



TRAINING INSTITUTE on STRANGULATION PREVENTION

Is a program of Alliance for HOPE International

101 West Broadway, Suite 1770
San Diego California 92101
Toll Free: 888-511-3522
Local: 619-236-9551
Fax: 619-236-0677
www.strangulationtraininginstitute.org

November 15, 2017

Subject: Radiographic Imaging of Non-Fatal Strangulation Patients

Dear Doctor:

The Training Institute on Strangulation Prevention has been asked to provide you with additional information about our [National Radiographic Imaging Guidelines](#) for survivors of non- and near-fatal strangulation assaults. We would like to inform you of local and national developments related to the handling of non-fatal strangulation assaults. It is the opinion of the Training Institute on Strangulation Prevention that the neck structures, most importantly the arterial vessels, of victims of non-fatal strangulation assaults must be evaluated for internal injuries. When a strangled victim/patient presents with a history of near or complete loss of consciousness, visual changes, petechiae, swelling, voice changes, painful swallowing or neurological symptoms with or without visible injuries, our medical advisors have concluded that is **medically necessary** to recommend imaging to rule out life-threatening injuries.

History of the Institute and Advisors

As background, the Training Institute on Strangulation Prevention (Institute) has been funded by the Department of Justice to address non-fatal strangulation cases since 2011. When the Institute was officially launched, our primary goal was to improve the handling of strangulation assaults by all disciplines. One of the first things we did was convene a small group of nationally recognized experts from around the country. Our advisors consist of academic and clinical emergency medicine physicians, forensic pathologists, forensic nurses, prosecutors, civil attorneys, law enforcement, researchers, trainers, advocates, and survivors.

Since 2011, our multi-disciplinary team of experts has grown. We now evaluate current practices, develop resource materials, provide training, and make recommendations to improve the handling of non-fatal strangulation assaults, including best practices for assessing a strangled patient in the emergency department.

In August 2016, our national advisors convened in San Diego, CA to address the health and safety concerns for the strangled victim/patient and our Medical Advisors specifically gathered to finalize their recommendations for the development of radiographic imaging guidelines. Our Medical Advisors had already been evaluating and researching this issue for approximately a year but ultimately adopted and unanimously endorsed the enclosed Imaging Recommendations in August 2016.



TRAINING INSTITUTE on STRANGULATION PREVENTION

Is a program of Alliance for HOPE International

101 West Broadway, Suite 1770
San Diego California 92101
Toll Free: 888-511-3522
Local: 619-236-9551
Fax: 619-236-0677
www.strangulationtraininginstitute.org

List of our National Medical Advisors/Experts:

The Medical Advisors who endorsed the Imaging Recommendations included distinguished national experts:

- Dr. William Smock, Chair of the Medical Advisory Committee for the Training Institute on Strangulation Prevention, Police Surgeon, Louisville Metropolitan Police Department and Clinical Professor of Emergency Medicine, University of Louisville School of Medicine, Louisville, Kentucky
- Dr. Cathy Baldwin Johnson, Medical Director, Family Physician, Alaska CARES, the Child Advocacy Center in Anchorage, Alaska
- Dr. William Green, Medical Director, California Clinical Forensic Medical Training Center; Clinical Professor, Emergency Medicine, University of California, Davis, Medical Center (retired); Co-founder and former Co-chair of the Forensic Medicine Section, American College of Emergency Physicians
- Dr. Dean Hawley, Professor of Pathology and Forensic Pathologist, Indiana University, Indianapolis, Indiana (retired)
- Dr. Ralph Riviello, Professor & Vice Chair of Clinical Operations, Emergency Medicine Drexel University College of Medicine, Pennsylvania, Past Chair, Forensic Medicine Section. American College of Emergency Physicians
- Dr. Heather Rozzi, Medical Director, Forensic Examiner Team, Pennsylvania State University, College of Medicine, Philadelphia Pennsylvania, Chair, Forensic Section. American College of Emergency Physicians
- Dr. Steve Stapcynski, Professor, Department of Emergency Medicine, University of Arizona, College of Medicine, Phoenix, Arizona
- Dr. Ellen Taliaferro, Medical Director, Keller Center for Family Violence Intervention, San Mateo Medical Center, California, Reno, Nevada (retired)
- Dr. Michael L. Weaver, Clinical Associate Professor, Emergency Medicine, University Missouri at Kansas City, MO, Medical Director, Clinical Forensic Care Program, Saint Luke's Health System, Kansas City, MO. Co-Founder and Past Chair, Forensic Medicine Section. American College of Emergency Physicians

Unanimous Expert Consensus

The Medical Advisors conducted a peer review process and identified over 200 strangulation articles. With the assistance of Boise State University, we published a comprehensive [bibliography](#). The Medical Advisors also shared their individual experiences, reviewed case studies, and discussed all options to detect and treat internal injuries associated with non-fatal strangulation assaults.



TRAINING INSTITUTE on STRANGULATION PREVENTION

Is a program of Alliance for HOPE International

101 West Broadway, Suite 1770
San Diego California 92101
Toll Free: 888-511-3522
Local: 619-236-9551
Fax: 619-236-0677
www.strangulationtraininginstitute.org

Dr. Dean Hawley, our advisor in forensic pathology, advised that the best way to determine the extent of internal injuries from strangulation was, and still is, an autopsy. An external visual examination is inadequate. Accordingly, for non-fatal strangulation assault, radiographic imaging is the preferred alternative.

After the August meeting, it was the unanimous consensus of our medical advisors that CTAs for the strangled patient must be the gold standard. CTAs are routinely ordered for patients who suffer some form of injury involving cervical hyperextension, rotation or hyperflexion, or near hanging with or without physical signs including seat belt abrasion across the neck or neck swelling, basal skull fracture involving the carotid canal, or cervical spine fracture involving the vertebral body. These mechanisms and types of injuries are all possible with the strangled patient given the case studies that have been brought to our attention. Unfortunately, non-fatal strangulation is often overlooked by the medical and legal communities. This oversight is understandable as, historically, the medical community believed a victim surviving a strangulation attempt without visible injury was fine. Most of the medical articles at that time were written by pathologists, and most of the published criminal cases concerned homicides.

It was only in 1995 that it was realized that the lack of training on the recognition and documentation of the strangled victim, the lack of published articles, and the lack of protocols and laws for addressing strangulation assaults without visible injury, was allowing many instances of strangulation to go undetected and unprosecuted.

Current Knowledge and Efforts

Today, the research is clear that more victims survive strangulation assault than originally thought. It is estimated that approximately 68% of domestic violence victims who are seeking medical assistance at hospitals, safety at shelters, and protection from law enforcement, have been the victims of non-fatal strangulation. Non-fatal strangulation is recognized as one of the most accurate predictors of eventual death from domestic violence. Non-fatal strangulation has immediate and long-term health consequences. Additionally, there are significant safety consequences for victims of non-fatal strangulation. In 2008, researchers found that **victims of intimate partner violence who are strangled even one time are 750% more likely to be murdered by the partner who strangled them.**

As a result of these findings, 45 states have passed laws making non-fatal strangulation a felony in order to prevent homicides and hold offenders accountable for the crimes they commit. Thankfully, the medical research and case law have finally caught up with each other, recognizing that strangulation is not only a predictor of future homicide, but



TRAINING INSTITUTE on STRANGULATION PREVENTION

Is a program of Alliance for HOPE International

101 West Broadway, Suite 1770
San Diego California 92101
Toll Free: 888-511-3522
Local: 619-236-9551
Fax: 619-236-0677
www.strangulationtraininginstitute.org

also that strangulation can cause serious bodily injury and/or substantial risk of death—something the military and law enforcement communities have known for years.

We have also learned that the ***men who strangle women are the men who are most likely to shoot and kill police officers and most likely to be involved in mass shootings.*** The link to health consequences for victims, and the risk to officers and public safety, recently led California's Governor Brown to sign into law SB40. SB40 addresses the seriousness of non-fatal strangulation by requiring officers to warn strangled victims about the immediate and long-term health consequences of strangulation. To track the most dangerous offenders, the new law also requires officers to document incidents of strangulation and suffocation in their reports.

The Danger of Strangulation

Professionals across the country are being trained about the seriousness and dangers of non-fatal strangulation assaults. They are being taught that strangulation involves the application of pressure and/or blunt force trauma to the neck. ***Injuries may include airway damage and compromise, stagnant hypoxia, anoxic brain injury, thyroid injury and risk of arterial damage to the carotid and vertebral arteries, stroke, and delayed death.*** As you know, when an artery is damaged, the normal pathophysiology is for the body to create a blood clot. If the clot becomes large enough, the clot can completely obstruct the normal flow of blood within the artery. Part of the clot can also break off and become an embolus that can travel “downstream” in the arterial tree eventually blocking an arterial branch causing a stroke. The time period from a patient's neck trauma to the time of presentation at a hospital with neurological symptoms, including strokes, can range from hours to years.

The Institute's Response

Currently, the Institute is collecting case studies of victims/patients who have suffered delayed deaths, strokes, carotid dissections, thyroid issues, miscarriages, and fractured hyoid bone and tracheal cartilages. These currently unpublished cases are being collected for purposes of publication to expedite adoption of national standards. In the meantime, these serious and life-threatening cases have created a sense of urgency. ***The Institute believes that it is critical that every medical professional and hospital immediately address the health and safety risks of patients of non-fatal strangulation assault.*** Our team of experts have identified the risk of a vascular injury, including carotid and vertebral dissections post-strangulation, as being at the top of the list, and the CTA as the best imaging modality for early detection of vascular injury.



TRAINING INSTITUTE on STRANGULATION PREVENTION

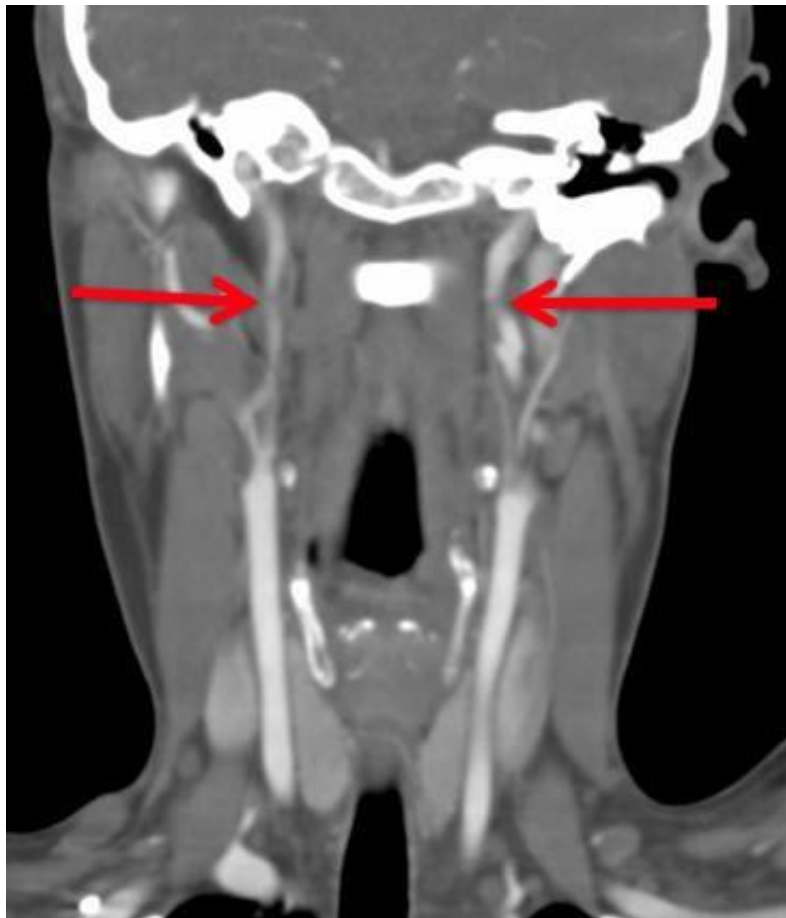Is a program of Alliance for HOPE International

101 West Broadway, Suite 1770
San Diego California 92101
Toll Free: 888-511-3522
Local: 619-236-9551
Fax: 619-236-0677
www.strangulationtraininginstitute.org

To acutely illustrate the need for a CTA in a patient with a history of strangulation, we would like to share with you the case of “Tanika,” a nurse who was strangled by her husband in San Diego. Tanika presented to a California emergency department six days post strangulation at the urging of a San Diego Police Department domestic violence detective. Tanika reported that she had been placed in a “choke hold” and may have lost consciousness.

She had no evidence of external neck trauma, had no difficulty swallowing, and was essentially asymptomatic as six days had passed from the strangulation. The detective

had received training from the Institute on the unseen dangers of neck compression and the need for radiographic imaging of neck vessels post strangulation.



The emergency physician appropriately ordered a CTA. The radiologist soon notified the physician that Tanika had bilateral carotid dissections (see image left).

She was anticoagulated for 9 months and survived without any morbidity. Had the emergency physician failed to order this life-saving CTA and discharged her home because she had no visible neck trauma and was asymptomatic, Tanika would have likely suffered a major stroke and may have died.

Bilateral internal carotid dissections in an asymptomatic strangulation victim.



TRAINING INSTITUTE on STRANGULATION PREVENTION

Is a program of Alliance for HOPE International

101 West Broadway, Suite 1770
San Diego California 92101
Toll Free: 888-511-3522
Local: 619-236-9551
Fax: 619-236-0677
www.strangulationtraininginstitute.org

CTA for the Strangled Patient is Medically Necessary

We recognize that the recent request for CTA imaging for the strangled patient is relatively new to your coverage area. We do not make recommendations for CTA imaging of strangled patients lightly. We understand that medical costs are significant and increasing. There must be well-considered limits to services, imaging, and treatment. However, our Medical Advisory Committee unanimously believes that a CTA for the strangled patient must be added to the list of medically necessary services that fall within national and state standards. Our research has determined that medical services such as CT scans have been found to be medically necessary by law, protocol, or policy if it is for the purpose of maintaining health, preventing disease, or diagnosing or treating an injury, illness, or disability.

We Anticipated Concerns

During our peer review process, our Advisors anticipated potential concerns the medical community may have with our imaging recommendations. In fact, one of our first considerations was whether imaging would be considered medically necessary. Based on the articles referenced in the imaging recommendations, case studies, and the collective experience of the medical advisors, the unanimous expert consensus was that imaging is medically necessary for the strangled patient.

Second, our Medical Advisory Committee discussed funding. We realize that funding may be an obstacle. We discussed various ways CT scans can be funded. We also discovered that the cost of CT scans can vary dramatically among service providers, ranging from less than \$1000 for outpatients and over \$1000 for emergency rooms. The availability of CT scans at the lower end of this cost range suggests that funding may be more manageable than some may believe. In any event, there is no doubt that CT scans can be covered by medical insurance, state Crime Victim Funds (as a payer of last resort), court orders and/or victim restitution, or waived by hospitals and/or negotiated to lower levels.

Our third consideration was radiation exposure. But we quickly determined together that radiation exposure is minor in comparison to the benefits of early diagnosis and treatment.

Lastly, we discussed the cost of negative findings and considered the benefits of ruling out a carotid dissection. In summary, the medical literature demonstrates that screening for blunt cerebrovascular injuries allows for early diagnosis and treatment, and is cost-effective because it prevents ischemic neurological events.



TRAINING INSTITUTE on STRANGULATION PREVENTION

Is a program of Alliance for HOPE International

101 West Broadway, Suite 1770
San Diego California 92101
Toll Free: 888-511-3522
Local: 619-236-9551
Fax: 619-236-0677
www.strangulationtraininginstitute.org

In one article, it was determined that patients with untreated injuries had an overall stroke rate of 21% but patients receiving early diagnosis and treatment almost universally avoided INE, concluding that “prompt diagnosis is critical to decrease the stroke rate in patients with BCVI” (American Journal of Surgery 190 (2005) (849-854)). In this same article, the authors conducted a cost analysis and determined that “any decrease in prolonged acute patient care will decrease costs to the patient, the insurance companies and ultimately society.” Similarly, in the article, “Screening for Blunt Cerebrovascular Injuries is Cost-Effective, the authors found that using CTAs decrease the stroke rate by 10% and provide a \$31,562 savings to society per patient screened.”

In reviewing the trauma literature, we found that the incidences of carotid or vertebral injuries varies between 1% and 2%. Because strangulation assaults were rarely considered in this body of research, we believe those statistics will ultimately prove to be much higher as we continue to collect case studies from around the country.

To expedite our efforts, we are working with the American College of Emergency Physicians, the International Association of Forensic Nurses, other nationally recognized medical organizations, the Department of Justice, the Department of Health and Human Services, and the Surgeon General of the United States of America to roll out this critical information to the public and the medical community. Given the prevalence of such assaults and the lethal and long-term consequences of strangulation, non-fatal strangulation is a public health issue.

Growing List of Hospitals Adopting the Imaging Recommendations

We are happy to report that as education is taking place across the country, hospitals are adopting the Institute’s recommendations for imaging. Hospitals in California, across the country, and around the world have implemented the recommendations. Our list includes some institutions that have the highest national stroke center designation from TJC and AHA/ASA. We encourage you to visit our website to see the growing list of hospitals who are pledging to adopt our gold standard of assessment for evaluating strangled patients. We have a team of experts who are willing to provide assistance and/or training in your area.

We also have the following webinars for your consideration:

- [Imaging Recommendations for the Strangled Patient/Victim](#) with Gael Strack, Dr. Smock, Dr. Green, Dr. Riviello and Dr. Weaver, July 2017
- [Understanding the Long Term Consequences of Non-Fatal Strangulation](#) with Dr. Smock, Sept 2016



TRAINING INSTITUTE on STRANGULATION PREVENTION

Is a program of Alliance for HOPE International

101 West Broadway, Suite 1770
San Diego California 92101
Toll Free: 888-511-3522
Local: 619-236-9551
Fax: 619-236-0677
www.strangulationtraininginstitute.org

We Welcome Your Support

We appreciate your consideration for our efforts to bring awareness to non-fatal strangulation assaults and patient consequences and hope you will consider consulting further with our Medical Advisory Committee. We can use your help in bringing awareness to the benefits of using imaging for the strangled patient and to the determination that CTAs are medically necessary to improve patient care and assessment, increase detection, and make accurate diagnoses. Our recommendations will reduce morbidity and mortality, and ultimately reduce claims for medical negligence.

Given the current state of our medical knowledge and the morbidity and mortality associated with a missed arterial injury in the neck, we are happy to consult further with your legal counsel about the profound liability exposure to your hospital systems and the medical providers who evaluate and treat strangled patients.

Respectfully,

Gael Strack, Esq.
CEO, Alliance for HOPE

Casey Gwinn, Esq.
President, Alliance for HOPE

And on behalf of the Physician's Medical Advisory Board:

William Smock, MS, MD, Chair

William Green, MD, FACEP

Ralph Riviello, MD, FACEP

Michael Weaver, MD, FACEP

Heather Rozzi, MD, FACEP



RECOMMENDATIONS for the MEDICAL/RADIOGRAPHIC EVALUATION of ACUTE ADULT, NON-FATAL STRANGULATION



Prepared by Bill Smock, MD and Sally Sturgeon, DNP, SANE-A

Office of the Police Surgeon, Louisville Metro Police Department

Endorsed by the National Medical Advisory Committee: Bill Smock, MD, Chair; Cathy Baldwin, MD; William Green, MD; Dean Hawley, MD; Ralph Riviello, MD; Heather Rozzi, MD; Steve Stapczynski, MD; Ellen Tailiaferro, MD; Michael Weaver, MD

- GOALS:**
1. Evaluate carotid and vertebral arteries for injuries
 2. Evaluate bony/cartilaginous and soft tissue neck structures
 3. Evaluate brain for anoxic injury

Strangulation patient presents to the Emergency Department

History of and/or physical exam with ANY of the following:

- **Loss of Consciousness** (anoxic brain injury)
- **Visual changes:** “spots”, “flashing light”, “tunnel vision”
- **Facial, intraoral or conjunctival petechial hemorrhage**
- **Ligature mark or neck contusions**
- **Soft tissue neck injury/swelling of the neck/cartoid tenderness**
- **Incontinence** (bladder and/or bowel from anoxic injury)
- **Neurological signs or symptoms** (LOC, seizures, mental status changes, amnesia, visual changes, cortical blindness, movement disorders, stroke-like symptoms.)
- **Dysphonia/Aphonia** (hematoma, laryngeal fracture, soft tissue swelling, recurrent laryngeal nerve injury)
- **Dyspnea** (hematoma, laryngeal fractures, soft tissue swelling, phrenic nerve injury)
- **Subcutaneous emphysema** (tracheal/laryngeal rupture)

Recommended Radiographic Studies to Rule Out Life-Threatening Injuries* (including delayed presentations of up to 6 months)

- **CT Angio of carotid/vertebral arteries** (*GOLD STANDARD* for evaluation of vessels and bony/cartilaginous structures, less sensitive for soft tissue trauma) *or*
- **CT neck with contrast** (less sensitive than CT Angio for vessels, good for bony/cartilaginous structures) *or*
- **MRA of neck** (less sensitive than CT Angio for vessels, best for soft tissue trauma) *or*
- **MRI of neck** (less sensitive than CT Angio for vessels and bony/cartilaginous structures, best study for soft tissue trauma) *or*
- **MRI/MRA of brain** (most sensitive for anoxic brain injury, stroke symptoms and intercerebral petechial hemorrhage)
- **Carotid Doppler Ultrasound** (*NOT RECOMMENDED*: least sensitive study, unable to adequately evaluate vertebral arteries or proximal internal carotid)

*References on page 2

History of and/or physical exam with:

- **No LOC** (anoxic brain injury)
- **No visual changes:** “spots”, “flashing light”, “tunnel vision”
- **No petechial hemorrhage**
- **No soft tissue trauma to the neck**
- **No dyspnea, dysphonia or odynophagia**
- **No neurological signs or symptoms** (i.e. LOC, seizures, mental status changes, amnesia, visual changes, cortical blindness, movement disorder, stroke-like symptoms)
- And **reliable home monitoring**

Discharge home with detailed instructions to return to ED if:
neurological signs/symptoms, dyspnea, dysphonia or odynophagia develops or worsens

Continued ED/Hospital Observation (based on severity of symptoms and reliable home monitoring)

(-)

- Consult Neurology/Neurosurgery/Trauma Surgery for admission
- Consider ENT consult for laryngeal trauma with dysphonia

(+)



RECOMMENDATIONS for the MEDICAL/RADIOGRAPHIC EVALUATION of ACUTE ADULT, NON-FATAL STRANGULATION



REFERENCES

(Recommendations based upon case reports, case studies, and cited medical literature)

1. Christe A, Thoeny H, Ross S, et al. Life-threatening versus non-life-threatening manual strangulation: are there appropriate criteria for MR imaging of the neck?. *Eur Radiol* 2009;19: 1882-1889
2. Christe A, Oesterhelweg L, Ross S, et al. Can MRI of the Neck Compete with Clinical Findings in Assessing Danger to Life for Survivors of Manual Strangulation? A Statistical Analysis, *Legal Med* 2010;12:228-232
3. Yen K, Thali MJ, Aghayev E, et al. Strangulation Signs: Initial Correlation of MRI, MSCT, and Forensic Neck Findings, *J Magn Reson Imaging* 2005;22:501-510
4. Stapczynski JS, Strangulation Injuries, *Emergency Medicine Reports* 2010;31(17):193-203
5. Yen K, Vock P, Christe A, et al. Clinical Forensic Radiology in Strangulation Victims: Forensic expertise based on magnetic resonance imaging (MRI) findings, *Int J Legal Med* 2007;121:115-123
6. Malek AM, Higashida RT, Halback VV, et al. Patient Presentation Angiographic Features and Treatment of Strangulation-Induced Bilateral Dissection of the Cervical Carotid Artery: Report of three cases, *J Neurosurg* 2000;92(3):481-487
7. Di Paolo M, Guidi B, Bruschini L, et al. Unexpected delayed death after manual strangulation: need for care examination in the emergency room, *Monaldi Arch Chest Dis* 2009;Sep;71(3):132-4
8. Dayapala A, Samarasekera A and Jayasena A, An Uncommon Delayed Sequela After Pressure on the Neck: An autopsy case report, *Am J Forensic Med Pathol* 2012;33:80-82
9. Hori A, Hirose G, Kataoka, et al. Delayed Postanoxic Encephalopathy After Strangulation, *Arch Neurol* 1991;48:871-874
10. Iacovou E, Nayar M, Fleming J, Lew-Gor S, A pain in the neck: a rare case of isolated hyoid bone trauma, *JSCR* 2011;7(3)
11. Oh JH, Min HS, Park TU, Sang JL, Kim SE, Isolated Cricoid Fracture Associated with Blunt Neck Trauma; *Emerg Med J* 2007;24:505-506
12. Gill JR, Cavalli DP, Ely SF, Stahl-Herz J, Homicidal Neck Compression of Females: Autopsy and Sexual Assault Findings, *Acad Forensic Path* 2013;3(4):454-457
13. Sethi PK, Sethi NK, Torgovnick J, Arsur E, Delayed Left Anterior and Middle Cerebral Artery Hemorrhagic Infarctions After Attempted Strangulation, A case report; *Am J Forensic Med Pathol* 2012;33:105-106
14. Clarot F, Vaz E, Papin F, Proust B, Fatal and Non-fatal Bilateral Delayed Carotid Artery Dissection after Manual Strangulation, *Forensic Sci Int* 2005;149:143-150
15. Molack J, Baxa J, Ferda J, Treska V, Bilateral Post-Traumatic Carotid Dissection as a Result of a Strangulation Injury, *Ann Vasc Surg* 2010;24:1133e9-1133e11
16. Plattner T, Bollinger S, Zollinger U, Forensic Assessment of Survived Strangulation, *Forensic Sci Int* 2005;153:202-207
17. Miao J, Su C, Wang W, et al. Delayed Parkinsonism with Selective Symmetric Basal Ganglia Lesion after Manual Strangulation, *J Clin Neurosci* 2009;16:573-575
18. Purvin V, Unilateral Headache and Ptosis in a 30-Year-Old Woman, *Surv Ophthalmol* 1997;42(2):163-168
19. Nazzal M, Herial NA, MacNealy MW: Diagnostic Imaging in Carotid Artery Dissection: A case report and review of current modalities; *Ann Vasc Surg* 2014;28:739.e5-739.e9
20. Chokyu TT, Miyamoto T, Yamaga H, Terada T, Itakura T: Traumatic Bilateral Common Carotid Artery Dissection Due to Strangulation: A case report; *Interventional Neuroradiology*;12:149-154, 2006

Traumatic Bilateral Common Carotid Artery Dissection Due to Strangulation

A Case Report

I. CHOKYU, T. TSUMOTO, T. MIYAMOTO, H. YAMAGA, T. TERADA, T. ITAKURA

Department of Neurological Surgery, Wakayama Medical University, Wakayama, Japan

Key words: common carotid artery, dissection, bilateral, carotid artery stenting, strangulation

Summary

We report a case of bilateral common carotid artery dissection due to strangulation successfully treated by stent placement, with a review of the literature. A 61-year-old woman was strangled by an apron strap. She was admitted to our hospital with tetraparesis, because of spinal cord injury. On the next day, her left hemiparesis aggravated and left facial palsy newly appeared. Diffusion weighted magnetic resonance imaging (MRI) showed new ischemic lesions in the right cerebral hemisphere. Aortography revealed bilateral common carotid artery dissection. Moreover, thrombus or intimal flap was recognized in the right common carotid artery. The right common carotid dissection was fixed with deployment of self expanding stents to prevent the aggravation of ischemic stroke at that time.

The contralateral lesion was also treated ten days later because small ischemic lesions were newly recognized in the left hemisphere on MRI. No new neurological deficit appeared after bilateral carotid artery stenting. Her paraparesis completely improved two months after the spinal cord injury. Carotid artery stenting using self expanding stents was especially effective as the treatment for bilateral carotid artery dissection.

Introduction

Carotid artery dissection (CAD) is rare, occurring spontaneously or secondary to trauma. Schievink reported that the annual incidence

rate of CAD was 2.6 per 100,000¹. Davis also reported CAD as occurring only in 0.08% of blunt trauma patients². Although CAD has been often missed in cases with few symptoms, it is increasing in young people in relation to the recent increase in motor-vehicle accidents.

Traumatic CAD is caused by sports, violence or traffic accidents, and can occur in unilateral or bilateral common carotid arteries. It sometimes causes cerebral infarction and results in poor outcome. On the other hand, spontaneous CAD occurs in unilateral common or internal carotid artery, and sometimes spontaneously cures.

CAD has been treated medically or surgically until endovascular therapy was introduced.

Anticoagulation is recommended as the standard medical treatment. On the other hand, surgical treatment such as arterial bypass is technically difficult and carries the risk of lower cranial nerve injury^{3,5}. Therefore, endovascular stent placement has recently been proposed as an alternative especially for bilateral lesions.

This paper describes a rare case of bilateral traumatic CAD secondary to strangulation treated by stent placement, and discusses our strategy of treatment with a review of the literature.

Case Report

A 61-year-old woman was caught in a conveyor belt. At that time, her neck was strangled by a strap of her apron (figure 1). She became unconscious and her pulse and respiration were

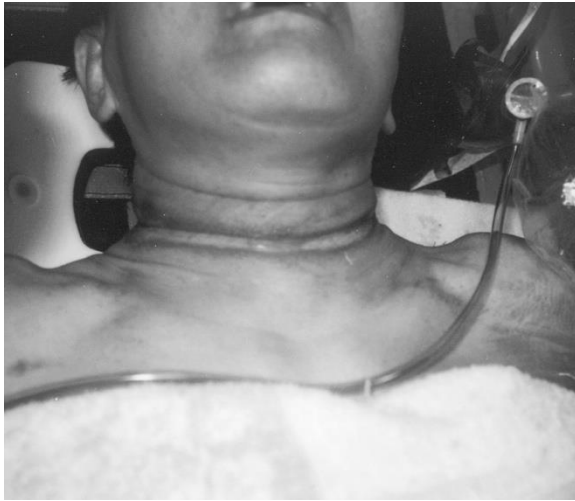


Figure 1 Photograph of the patient on admission. Her neck is strangled by an apron strap.

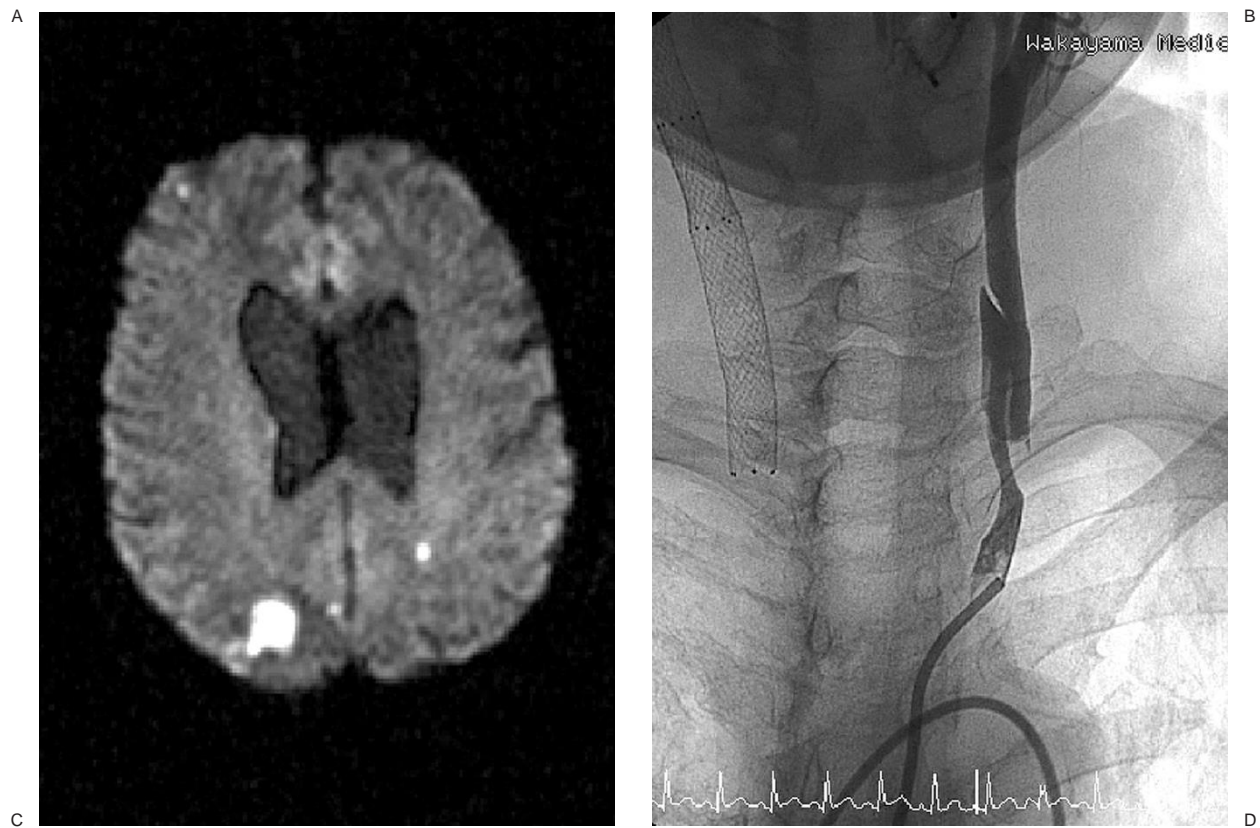
weak. On admission to our hospital, she was conscious with tetraparesis^{2,5} and hypesthesia in her extremities. A brain CT scan showed no abnormal lesions, but cervical MR scan revealed intramedullary abnormal intensity in the C5/6 spinal cord. She was diagnosed as spinal cord injury and received high-dose steroid therapy (1000 mg/day) after admission. On the next day, however, her left hemiparesis aggravated to^{1,5}, including left facial palsy, and

carotid bruit was audible at her right neck. Magnetic resonance angiography showed dissection of the bilateral common carotid arteries, and diffusion-weighted MRI revealed new ischemic lesions in the right hemisphere (figure 2A). Diagnostic angiography confirmed dissection of bilateral common carotid arteries, and showed a defect of contrast medium distal to the right dissected lesion suggesting thrombus or intimal flap (figure 2B). We considered that cerebral infarction was caused by artery-to-artery embolism from the right common carotid artery dissection. To prevent further embolism or acute occlusion of the dissected common carotid artery, we performed stent placement for the right common carotid artery simultaneously.

Under local anesthesia, a 9F guiding catheter was advanced into the right common carotid artery (CCA). As the dissected lesion was too long to cover with a single stent, two stents were necessary to cover the entire lesion. A guard wire (PercuSurge system; Medtronic, Inc., Minneapolis, MN) was navigated into the right internal carotid artery beyond the dissection, and primary stenting was performed with an 8x 40 mm SMART stent (Cordis Endovascular, Miami Lakes, FL) for the distal part of dissection under distal protection. Then, a 9x 60 mm SMART stent was deployed in the proximal part in overlapped

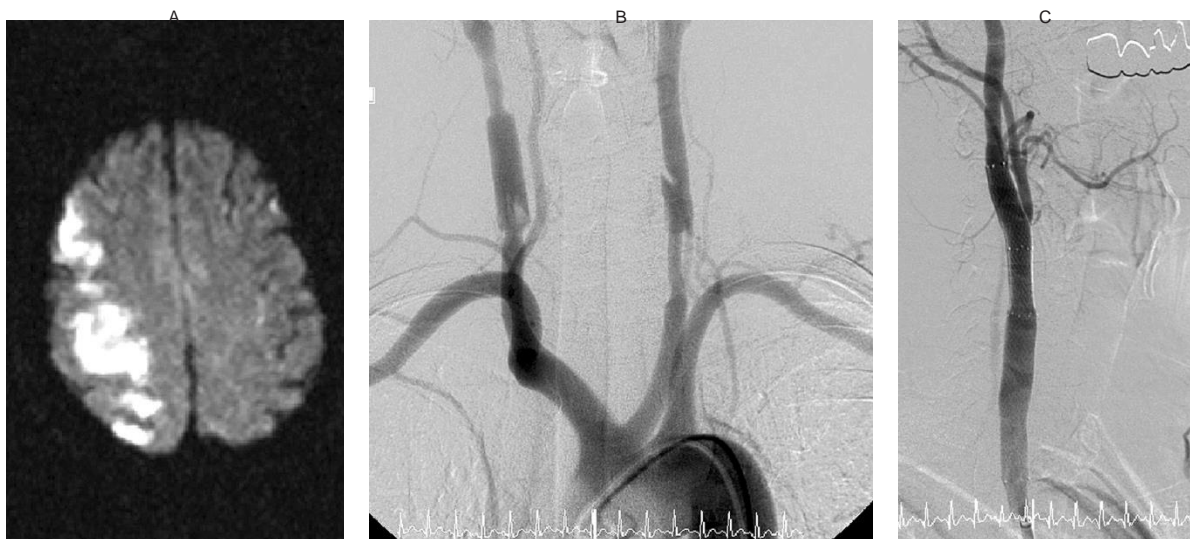
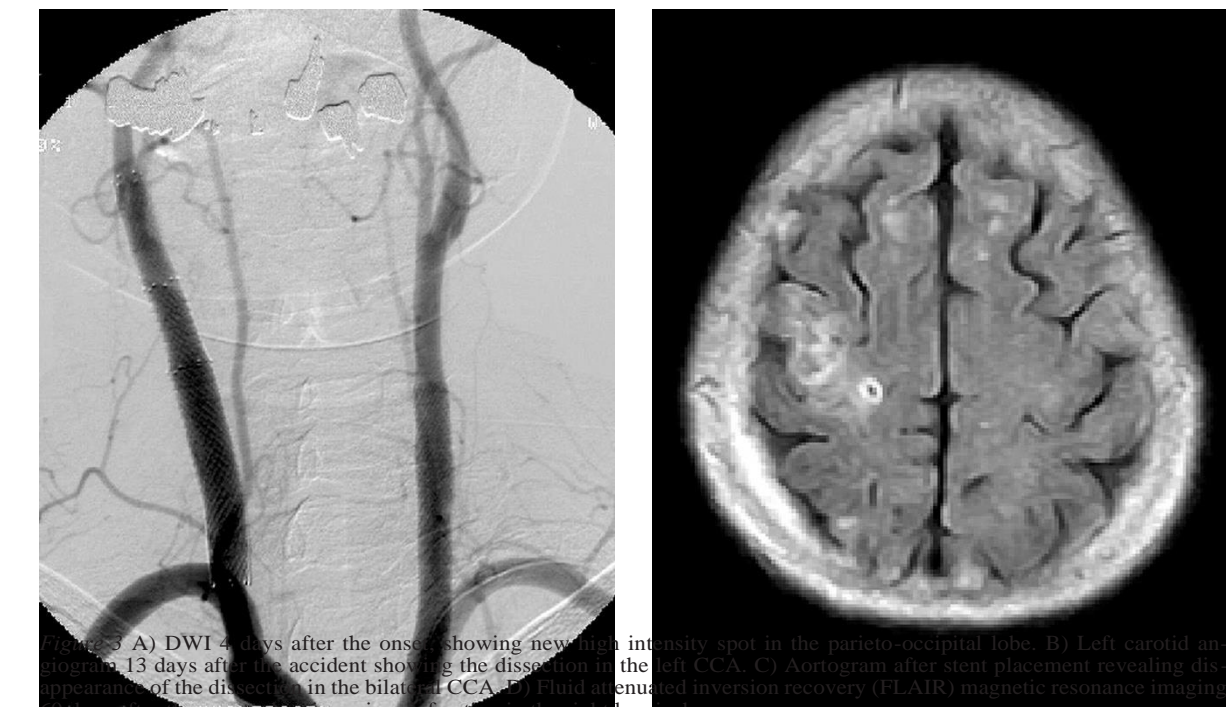
Figure 2 A) Diffusion-weighted magnetic resonance imaging (DWI) one day after the onset, showing new ischemic lesions in the right hemisphere. B) Aortogram one day after the trauma, showing bilateral common carotid dissection. Thrombus or intimal flap is recognized in the right common carotid artery (CCA). C) Right carotid angiograms after stent placement (right oblique view), revealing good patency of the right CCA.



Figures 3 A) DWI 4 days after the onset, showing new high intensity spot in the parieto-occipital lobe. B) Left carotid angiogram, 13 days after the accident showing the dissection in the left CCA. C) Aortogram after stent placement revealing disappearance of the dissection in the bilateral CCA. D) Fluid attenuated inversion recovery (FLAIR) magnetic resonance imaging 60 days after the onset, showing minor infarction in the right hemisphere.

Table 1 Literature review of carotid artery dissection.

Case No.	Authors and Year	Age/Sex	Etiology of Dissection	Side	Treatment	Time Interval after Onset	Initial Symptoms
1	Anne et Al, 2002	24/f	motor vehicle accident	bilateral	anticoagulation	1 day	GCS 8,Lt hemiplegia
2	Anne et Al, 2002	25/f	motor vehicle accident	bilateral	anticoagulation	6 days	drowsiness, Rt hemiparesis,Rt Honer
3	Bejjani et Al, 1999	53/m	direct blow	rt	stenting	3 months	Lt hemiparesis
4	Bejjani et Al, 1999	18/m	gunshot	rt	stenting	8 days	Lt hemiparesis
5	Bejjani et Al, 1999	33/f	motor vehicle accident	lt	stenting	1 day	Rt hemiplegia
6	Bejjani et Al, 1999	55/f	lift a heavy load	rt	stenting	2 weeks	Lt neck pain,headache
7	Doi et al., 2004	21/m	motor vehicle accident	rt	stenting	2 hours	JCS 20,Lt hemiparesis
8	Duncan et Al,2000	39/m	motor vehicle accident	bilateral	anticoagulation	a few hours	Lt hemiplegia
9	Fabrizio et Al,2004	17/m	motor vehicle accident	bilateral	stenting	?	Lt hemiparesis
10	Khaqan et Al,1996	41/f	motor vehicle accident	bilateral	anticoagulation	1 day	Lt lower limb paresis
11	Malek et Al,2000	37/f	domestic abuse	bilateral	stenting	3 months	Rt hand weakness and numbness
12	Malek et Al,2000	43/f	domestic abuse	bilateral	stenting	3 months	Lt hemiparesis
13	Malek et Al,2000	24/f	domestic abuse	bilateral	anticoagulation	6 months	JCS 300
14	Malek et Al,2000	37/f	hanging injury	lt	stenting	3 months Rt	hemiparesis, leg numbness, and dysphagia
15	Malek et Al,2000	44/f	motor vehicle accident	lt	stenting	4 months	dysphasia, Rt arm weakness, and numbness
16	Noguchi et Al, 1992	50/f	hanging injury	rt	carotidendoartectomy	2 years	Lt arm 4/5, hypoesthesia
17	Okada et Al, 1999	30/f	motor vehicle accident	lt	bypass surgery	7 months	Rt hemiparesis
18	Okada et Al, 1999	42/f	motor vehicle accident	rt	bypass surgery	2 days	Lt hemiparesis
19	Okada et Al, 1999	58/f	motor vehicle accident	rt	bypass surgery	10 years	Lt hemiparesis
20	Okada et Al, 1999	41/f	hanging injury	rt	bypass surgery	2 years	dizziness
21	Okada et Al, 1999	42/m	direct blow	rt	bypass surgery	2 years	Lt hemiparesis
22	Okuchi et Al, 1999	29/m	motor vehicle accident	rt	anticoagulation	11days	JCS 200
23	Scavee et Al, 2001	53/m	motor vehicle accident	rt	stenting	6 weeks	dizziness,neck pain
24	Stahlfeld et Al, 2002	39/m	ride on a rollar coaster	rt	anticoagulation	3 weeks	headache, Lt eye pain, Lt temporoparietal numbness

fashion. These two stents covered the entire lesion and the thrombus or intimal flap disappeared immediately (figure 2C). After stenting, anticoagulation therapy (heparin 10,000 units/day) was maintained for ten days. Her neurological symptoms did not change perioperatively.

The contralateral lesion was also treated ten days after onset, because diffusion weighted MRI on the fourth day showed a new ischemic lesion in the left parietal lobe in spite of anticoagulation (figure 3A). Carotid artery stenting was performed in the same manner as the first. After distal protection, an 8x 60-mm X-pert stent (Abott Vascular Devices Chicago Illinois USA) was deployed to cover the entire lesion of the CCA dissection (figure 3B,C).

She was treated with an antiplatelet drug (bispaspirin 100 mg/day) after the stent placement for the left carotid lesion. Her paraparesis improved to full strength two months after the injury. Angiography at the 23rd day revealed widely patent CCA without any thrombus in the bilateral common carotid artery, and follow-up MRI at the 60th day showed no new cerebral infarction in the brain (figure 3D).

Discussion

The etiology of CAD caused by neck trauma is generally considered as follows. (A) The CCA is stretched by neck hyperextension during rotatory movement of head. (B) The CCA is compressed to the lateral mass of the atlas and transverse processes of the spine during contralateral flexion of the neck. (C) The CCA is directly injured by a blow⁶. We reviewed 43 patients who had diagnosis of traumatic CAD from 1988 to 2004, and found that CAD caused by (A) or (B) had a tendency to occur in the unilateral internal carotid artery. As for the cause of CAD, it was often associated with motorcar or bicycle accidents. On the other hand, CAD due to strangulation was reported to be rare. In our case, bilateral CAD was considered due to direct injury to the common carotid artery at the neck. As her neck was strangled by her apron strap, bilateral CCAs were easily compressed by the strap.

When CAD occurs, thrombus may be formed near the dissection, and causes distal embolism or acute occlusion. In cases of traumatic CAD, it is well known that there are more cases with focal signs caused by cerebral embolism

than those with headache alone⁷. In 25 cases whose initial symptoms were reported in the literature, hemiparesis was identified in 19 cases, and headache was only in two patients⁵⁻¹⁶. According to the interval from accident to onset of symptoms, it has been considered that neurological signs due to CAD generally occur within 24 hours¹⁴. In our review of the literature, however, symptoms occurred within 24 hours only in two out of 25 cases. On the other hand, in 11 out of 23 patients, symptoms occurred after a few months, and most of these patients suffered from cerebral ischemia. Therefore, we should consider that it is necessary to look for cerebral embolism for a long time, even in asymptomatic patients.

In general, CAD has been treated medically, especially in asymptomatic cases. Heparin was continued for about one week, and followed by oral anticoagulant with warfarin for three to six months. When frequent transient ischemic attack or cerebral infarction occurs, surgical treatment should be considered^{3,17,18}. Surgical treatment includes interposition of the saphenous vein graft, extracranial to intracranial arterial bypass, and carotid endarterectomy. In seven out of 25 cases in our review, surgical treatments were selected, and five of them received reconstruction with vein graft. Okada et al reported the outcome of surgical treatment was poor in their series⁵. As the reason for poor results, it was considered that surgery must be performed under anticoagulation and the rate of graft vessel patency was low. Moreover, especially in a case of bilateral CAD as our case, surgery may cause laryngeal nerve palsy bilaterally. On the other hand, stent placement was done for ten out of 25 cases and their results were good in all cases. Recently, stent placement proved to be good for high-risk patients for carotid endarterectomy in the SAPPHERE study¹⁹. Therefore, stent placement is considered more suitable than direct surgery, as a treatment for bilateral CAD.

Carotid artery stenting allows immediate disappearance of dissected lumen with reperfusion to ischemic brain. In particular, the self-expanding stent we used in our case can resolve dissection by compressing the intimal flap to the vessel wall. Since the vessel wall of traumatic dissected carotid artery does not have atheromatous plaque as seen in cases of atherosclerotic carotid artery stenosis, the risk of embolic complication and restenosis seems low,

and strong medication is considered unnecessary after stenting.

At present, although guidelines for treatment of CAD are lacking, we consider it is better to perform stent placement for traumatic CAD in symptomatic cases as soon as possible.

Even in asymptomatic case, there is a possibility of causing cerebral embolism in the chronic phase as shown in previous reports. Therefore, we consider that it is reasonable to perform stent placement when new lesions are detected on MRI.

References

- Schievink WI, Mokri B, Whisnant JP: Internal carotid artery dissection in a community, Rochester, Minnesota, 1987-1992. *Stroke* 24: 1678-1680, 1993.
- Duncan MA, Dowd N et Al: Traumatic bilateral internal carotid artery dissection following airbag deployment in a patient with fibromuscular dysplasia. *Br J Anaesth* 85: 476-478, 2000.
- Benjjani GK, Monsein LH et Al: Treatment of Symptomatic Cervical Carotid Dissection with Endovascular Stents. *Neurosurgery* 44: 755-761, 1999.
- Cohen JE, Leker RR et Al: Emergent Stenting to Treat Patients with Carotid Artery Dissection. *Stroke* 34: 254-257, 2003.
- Okada Y, Shima T et Al: Traumatic dissection of the common carotid artery after blunt injury to the neck. *Surg Neurol* 51: 513-20, 1999.
- Noguchi K, Matsuoka Y et Al: A case of common carotid artery stenosis due to hanging. *No Shinkei Geka* 20: 1185-1188, 1992.
- Lucas C, Moulin T et Al: Stroke Patterns of Internal Carotid Artery Dissection in 40 Patients. *Stroke* 29: 2646-2648, 1998
- Chomel A, Verneh M et Al: Traumatic bilateral dissections of the internal carotid artery: An infrequent diagnosis not to be missed. *J Neurosurg Anesthesiol* 14: N° 4, 2002.
- Anson J, Crowell RM: Cervicocranial arterial dissection. *Neurosurgery* 29: 89-96, 1991.
- Doi A, Deguchi J et Al: Traumatic Internal Carotid Artery Dissection Due to Compression by a Helmet Strap. *No Shinkei Geka* 32: 1279-1282, 2004.
- Fabrizio F, Fillippo MS et Al: Stent Repair of Bilateral Post-Traumatic Dissections of the Internal Carotid Artery. *J Endovascular* 11: 517-521, 2004.
- Leys D: Cervical artery dissections. *Eur Neurol* 37: 3-12, 1997.
- Malek AM, Higashida RT et Al: Patient presentation, angiographic features and treatment of strangulation-induced bilateral dissection of the cervical internal carotid artery. *J Neurosurg* 92: 481-487, 2000.
- Mokri B, Piegras DG, Wayne HO: Traumatic dissections of the extracranial internal carotid artery. *J Neurosurg* 68: 189-197, 1988.
- Scavee V, De Wispelaere JF et Al: Pseudoaneurysm of the internal carotid artery: treatment with a covered stent. *Cardiovasc Intervent Radiol* 24: 283-285, 2001.
- Watridge CB, Muhlbaier MS, Lowery RD: Traumatic carotid artery dissection: diagnosis and treatment. *J Neurosurg* 71: 854-857, 1989.
- Malek AM, Higashida RT et Al: Endovascular Management of Extracranial Carotid Artery Dissection Achieved Using Stent Angioplasty. *Am J Neuroradiol* 21: 1280-1292, 2000.
- Uno M, Ueda S et Al: Management and long-term follow-up results in patients with carotid artery dissection. *No Shinkei Geka* 25: 417-423, 1997.
- Yadav JS, Wholey MH et Al: Protected Carotid-Artery Stenting versus Endarterectomy in High-Risk Patients. *N Engl J Med* 351: 1493-1501, 2004.

Isao Chokyu, M.D.
 Department of Neurological Surgery
 Wakayama Medical University
 Wakayama, Japan
 811-1 Kimiidera, Wakayama city
 Wakayama 641-0012, Japan
 E-mail: chokyui@wakayama-med.ac.jp